




Neotropical Helminthology



ORIGINAL ARTICLE / ARTÍCULO ORIGINAL

CUTANEOUS MYIASIS BY *COCHLIOMYIA HOMINIVORAX* COQUEREL, 1858 (DIPTERA: CALLIPHORIDAE) ASSOCIATED WITH ORAL NEOPLASIA, IN GERIATRIC PATIENT

MIASIS CUTÁNEA POR *COCHLIOMYIA HOMINIVORAX* COQUEREL, 1858 (DIPTERA: CALLIPHORIDAE) ASOCIADA CON NEOPLASIA ORAL, EN PACIENTE GERIÁTRICO

Julia Castro-Hidalgo¹; Nelly Milla Nuñez¹; Asucena Naupay Igreda² & Javier Zegarra Velit³

¹ Control Laboratory of Arthropods and Vectors. National University of San Marcos Faculty of Biological Sciences

² Laboratory of Human and Animal Parasitology. National University of San Marcos. Faculty of Biological Sciences

³ Private medical center

*Corresponding author: E-mail: jch4920@hotmail.com

ABSTRACT

We report a case of a specific cutaneous human myiasis, associated to oral neoplasia. The presentation of this case corresponds to a 78 years old adult male patient coming from Chorrillos district, Lima, Peru who at the time of being treated at a medical center, presented an open ulcerative wound in the lower right maxillary in which larvae of flies of different stages were observed. Biological material extracted from the wound was identified as *Cochliomyia hominivorax* (Coquerel, 1858) (Diptera: Calliphoridae), by the morphological characteristics of third instar larvae through the optical and scanning electron microscopy. In this case, the presence of *C. hominivorax* was favoured by the oral lesion of the patient who attracted flies to lay their eggs on the edge of the lesion.

Key words: *Cochliomyia hominivorax* – cutaneous myiasis – oral neoplasia – Peru – third larvae stage

RESUMEN

Se registra un caso de miasis cutánea específica, asociada a neoplasia bucal. La presentación del caso corresponde a un paciente geriátrico de sexo masculino, de 78 años de edad, procedente del distrito de Chorrillos, Lima, Perú que al momento de ser atendido en la clínica, presentaba una herida ulcerosa abierta, en el maxilar inferior derecho en la que se observó gran cantidad de larvas de diferentes estadios. El material biológico extraído de la herida del paciente fue identificado como *Cochliomyia hominivorax* (Coquerel, 1858) (Diptera: Calliphoridae), por las características morfológicas de la larva de tercer estadio a través de la microscopía óptica y electrónica de barrido. En este caso clínico, la presencia de *C. hominivorax* se vio favorecida por la lesión bucal del paciente que permitió atraer a las moscas para que coloquen sus huevos en el borde de la lesión.

Palabras clave: *Cochliomyia hominivora* – larvas de tercer estadio – miasis cutánea – neoplasia oral

INTRODUCTION

Myiasis is a zoonotic infestation that affects the live or necrotic tissues of human and other vertebrate animals and is caused by different larval stages of flies, which during a certain period feed on live or dead tissues or body fluids from the natural cavities of the host, or by the intake of contaminated food. Myiasis are called "gusaneras", "bicheras", "coqueras" and are produced by species of flies of the Order Diptera: Suborder Brachycera (Acha & Szyfres, 2003; Carles-Tolrá, 2015). The necrobiontofagas larvae invade wounds or lesions, body regions with purulent discharges such as nose, ears or genitals, reaching up to the living tissues. These flies are part of the cadaveric fauna. Worldwide there are 330,570 million people at risk of being affected by this parasitism (Botero & Restrepo, 2012). In humans, the infestation is accidental and the risk groups are immunocompromised people, indigents, elderly people and animal breeding staff. The main risk factors are open wounds, exposure of ulcers, hemorrhoids, bacterial infection of wounds or natural cavity, sleeping outdoors, poor hygiene, not wearing footwear, eating contaminated food. Myiasis are rapidly evolving, very aggressive and with tissue destruction and the main locations occur in the skin, mouth, eyes, breasts, intestinal tract and genitourinary (Coronel *et al.*, 2016).

Myiasis are classified according to the type of tissue they invade, by the organ they affect (foruncular, cutaneous, cavitary, and intestinal), by the type of invasive process (obligatory, facultative and accidental) and by the clinical forms that have been found in man. Cutaneous myiasis have two clinical forms according to the invaded tissue: forunculosa caused by *Dermatobia hominis* (Linnaeus, 1781), and ulcers such as those caused by *Cochliomyia hominivorax* (Coquerel, 1858), *Sarcophaga haemorrhoidalis* (Fallén, 1817) and *Hypoderma bovis* (Linnaeus, 1758) (Páez & Villa, 2017).

Cochliomyia hominivorax known as "screw worm", is a diptera of the Family: Calliphoridae, which seriously affects livestock and especially cattle. The distribution of the screw worm is conditioned to the climatic changes, the low temperatures prevent them from surviving, or,

because the animal population is insufficient to maintain the biological cycle (Graham, 1985; Villarreal *et al.*, 1993).

The females are attracted by wounds or secretions where they lay their eggs at the edges of the wounds, in the injured mucous membranes that are associated with the natural openings of the body such as the sinuses, eye sockets, mouth, ears and vagina. They deposit an average of 200 eggs (between 10 and 490) in a characteristic flat, roof-shaped mass (Becerril, 2014).

Larvae of *C. hominivorax* cause facultative or semi-specific myiasis, have occasional parasite life and invade lesions or purulent body regions. The larvae hatch before 24 h after oviposition and begin to feed on tissue fluids, with the head facing down and penetrating the hole in the wound, causing massive tissue destruction. The larvae reach maturity between 4 and 8 days after hatching and leave the wound, fall to the ground, bury themselves and initiate pupation. The period of life under normal conditions from egg to adult is 3 to 4 weeks. The wounds tend to attract other flies which also deposit their eggs aggravating myiasis in this way (Francesconi & Lupi, 2012). The objective of the present work was to describe the case of cutaneous myiasis of a geriatric patient, with an advanced stage of oral carcinoma, through the taxonomic identification of the third stage larvae extracted from the lesion.

MATERIAL AND METHODS

Male patient, 78 years old, retired, native of Germany, peruvian resident for 40 years, of protestant religion, coming from La Encantada de Villa urbanization, district of Chorrillos in Lima, Peru. The patient enters the emergency of the medical center having a history of malignant neoplasm of the mouth and having received chemotherapy treatment.

The patient was transferred from another local clinic, with a nasogastric tube and when he was received in the clinic, he had 10 g hemoglobin, 3,300,000 cc red blood cells and 9,950 mm 3

leukocytes. A tumor and lesion were observed in the right maxilla region, irregularly shaped, 5 cm long, 3 cm in diameter and 2.5 cm deep; of net edges, bleeding bed and multiple tunnels at the base of the wound (Fig.1). In addition, the patient showed perforated deep ulcers, which communicated with the oral region, with the presence of necrotic tissue, bloody exudate and foul odor, from which 28 larvae of different size emerged.

We proceeded to the extraction and separation of the larvae by stages and they were fixed in 70% ethyl alcohol for later taxonomic identification (Fig.2).

Identification of larval forms

The identification of the species was performed on larvae that were at the beginning of the third stage (L₃) because they were the most robust, 15-16 mm long, creamy white with reduction in thickness from the cephalic segment to the sixth segment and then decreasing towards the posterior end.

The L₃ were heavily armed with large spines of 1 to 3 points, often 1 or 2 spines on its cuticle visible to the naked eye. From the 2nd to the 9th segment they were observed surrounded with a band of thorns organized in irregular rows, being longer than the previous rows and in the 7th and 9th segments they presented thorns in the posterior margins, reduced to one or two rows and confined to the ventral surfaces.

The 10th segment with an anterior band of spines somewhat reduced and usually interrupted on the back, with ventral and ventrolateral spines a little scattered laterally and dorsally. The 11th segment with an incomplete anterior band and smaller spines; and in the posterior margin a band of 2 or 3 rows of anterior curved spines were observed. The 12th segment presents restricted spines to the ventral and ventrolateral surfaces. The cephalopharyngeal apparatus with dorsal arms longer than the ventral ones (Fig. 3).

The anterior spiracles of L₃ are small fan-shaped with finger-like extensions located near the base of the second segment, usually with 6 to 11 papillae each. To observe the posterior spiracles, the 12th segment was cut and the vertical spiracular plates were observed, those that showed imperceptible

button, incomplete perithema of dark pigmentation, with strongly pigmented tracheal trunks. Through the morphological characteristics of L₃ larvae, *C. hominivorax* was identified, using the taxonomic keys of Dale (1985), Gómez *et al.* (2008) and Florez & Wolff (2009) (Fig. 4).

To corroborate our diagnosis the L₃ were processed by scanning electron microscopy, using the critical point desiccator brand Electron Microscopy Sciences Model: EMS850 and the gold metalizer brand: SPI supplies. The microscopic scanning observation revealed the same characteristics found with optical microscopy (Fig.5)

RESULTS AND DISCUSSION

Myiasis caused by *C. hominivorax* is a zoonotic parasitism recognized by the International Office of Epizootics (OIE), and its notification is obligatory. In animals, the main risk factor is open wounds that can occur due to natural causes or caused by man due to practices during the cattle exploitation, and another factor are the natural openings of the host. (Forero *et al.*, 2007). This infestation in humans is almost always accidental and can be caused by opportunistic dipterous. Parasitism depends on environmental factors such as the presence of gravid flies, season and area of residence. There are also the risk factors that the host provides such as the poor hygiene condition; inadequate treatment of wounds and ulcers; exposed and suppurative lesions that are attractive for the oviposition of flies. Another factor is the patient's condition (age, physical limitation, alcoholism, drug addiction, chemotherapy treatment) and / or patient's health status, as well as the presence of comorbidities (cancer, diabetes and tuberculosis) (Reinoso & Alemán, 2016).

Patients with neoplasms in cavities, with open wounds and skin diseases offer the possibility of other infections such as cutaneous myiasis.

Visciarelli *et al.* (2003) observed in a 36 years old patient with pediculosis, wounds on the scalp that were superinfected with larvae of *C. hominivorax*. The patient was a field worker and had neglect of his personal hygiene, malnutrition and a head

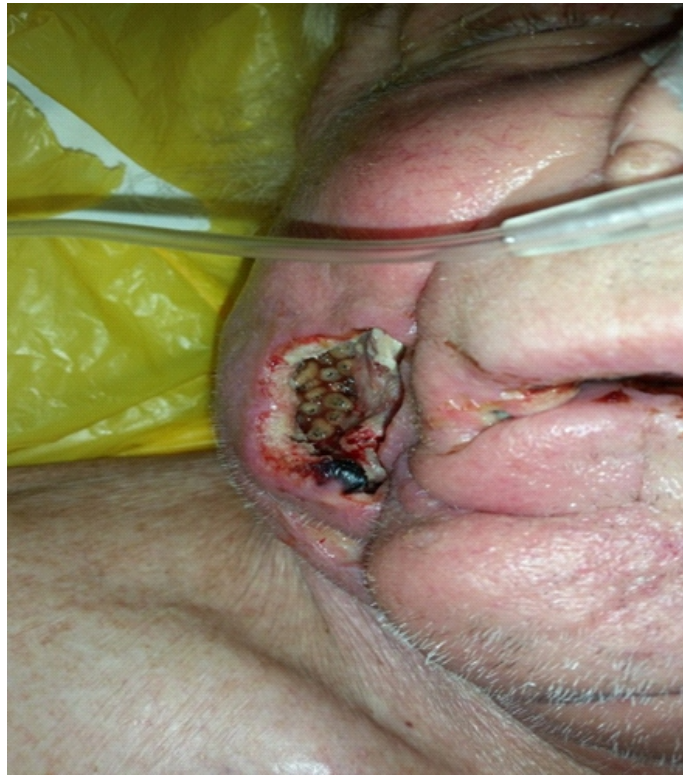

Figure 1. Patient with lesion in the region of the right maxilla where larvae of *C. hominivorax* was observed.

injury with a serosanguineous secretion.

In children with pyodermatis on the scalp, larvae of flies have also been extracted and by the stench presented by the wounds, they were identified as *C. hominivorax* (Miranda, 2007). Post-scratching lesions in a 3 years old patient with chickenpox were also superinfected with *C. hominivorax* larvae (Heizenreder *et al.*, 2009).

In prostrate patients, they also show some susceptibility to acquire this type of opportunistic infections, thus a case of myiasis in the oral cavity is reported by *C. hominivorax* in a patient prostrate due to Parkinson's disease, from Huacho (Lima, Peru) (Espinoza *et al.*, 2009).

Trombetta *et al.* (2009), reported a case of cutaneous myiasis in a 32-year-old man with a history of alcoholism and drug addiction, which had a head wound with severe bacterial infection. 71 larvae were extracted from the wound which were identified as *C. hominivorax*. This infestation is almost always accidental in humans and in this case was favored by the condition of the patient.

Myiasis is the infestation of living vertebrates by fly larvae that feed for at least part of their development on the host's dead or living tissues, body substances, or ingested food. The occurrences of traumatic myiasis in humans and animals in urban and rural environments represent serious economic and public health concerns (Zumpt, 1965).

Batista da Silva *et al.* (2011), reported a 49-year-old tracheostomized man undergoing chemotherapy treatment who was parasitized in the hospital in São Gonçalo, Rio de Janeiro, Brazil, by larvae of the screwworm, *C. hominivorax* in the thoracic cavity.

In Tucumán (Argentina), Olea *et al.* (2014), was reported the first case of cutaneous myiasis in a patient diagnosed with type II diabetes, with ten years of evolution and with neuropathy. The 54-year-old male patient presented with an ulcer approximately 4 cm in diameter in the right foot from which 5 larvae were extracted. Third instar larvae were identified as *C. hominivorax* and adults emerged at 12 days confirming the diagnosis.

through their morphological characteristics.

A case of oral myiasis caused by *C. hominivorax* was reported in a person with neuropsychomotor limitation who presented lesions in the maxilla and mandible. They extracted 45 maggots from the lesions and 75 when general anesthesia and nasotracheal intubation were applied to the patient. This study recommends dentists who must recognize parasites that affect the oral cavity (Pereira *et al.*, 2015). Reinoso & Alemán (2016), report the first case of maxillary myiasis in Cuenca (Ecuador), in a 24-year-old patient with prolonged mouth opening, spastic paralysis and muscular rigidity in all four extremities. Third instar larvae of *C. hominivorax* were extracted from the gingival mucosa and the tear orifice. By surgical debridement they found larval tunnels in the upper labial frenum and in the palate presenting great bloody flow.

A retrospective study was conducted in Lambayeque (Peru), of the cases diagnosed of myiasis in two hospitals from January 2012 to December 2015, which were compiled from the clinical files. They chose the cases in which larval development was observed and a clinical profile compatible with myiasis. There were 9 cases of myiasis, of which two were pediatric patients, one adult and six elderly. Four of the nine patients were male. The identified species were *D. hominis* and

Cochliomyia hominivorax. Patients with *D. hominis* presented skin lesions and abscesses while cases with *C. hominivorax* had a history of tuberculosis or cancer of the larynx or breast (Failoc-Rojas *et al.*, 2018).

In the present clinical case, the patient had received chemotherapy treatment for presenting oral neoplasia, and lesions of the mouth, buccal mucosa and cheek were infected with larvae of *C. hominivorax*, being this the first time were the association cutaneous myiasis- oral neoplasia is mentioned in literature. The importance of a quick diagnosis is highlighted by the aggressiveness of the biontophage larvae that are capable of destroying even bone tissue (Pérez-Caballero *et al.*, 2012).

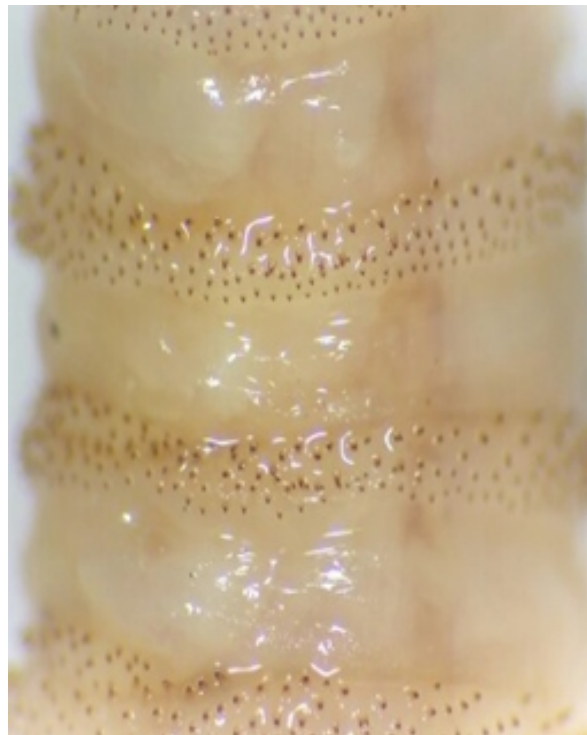
The role of *C. hominivorax* as a producer of specific human miasis, favored by the patient's condition, is highlighted (Calderón *et al.*, 1995; Maguiña-Vargas *et al.*, 2005; Mengarelli & Cevallos 2012; Domínguez *et al.*, 2016). Cutaneous myiasis are the most frequent in rural environments, however in the case that occurs, occurred in urban environment.

Ethical responsibility


The authors declare that no human experiments have been carried out for this investigation.



Figure 2. *Cochliomyia hominivorax* third stage larvae extracted from the patient's injury.

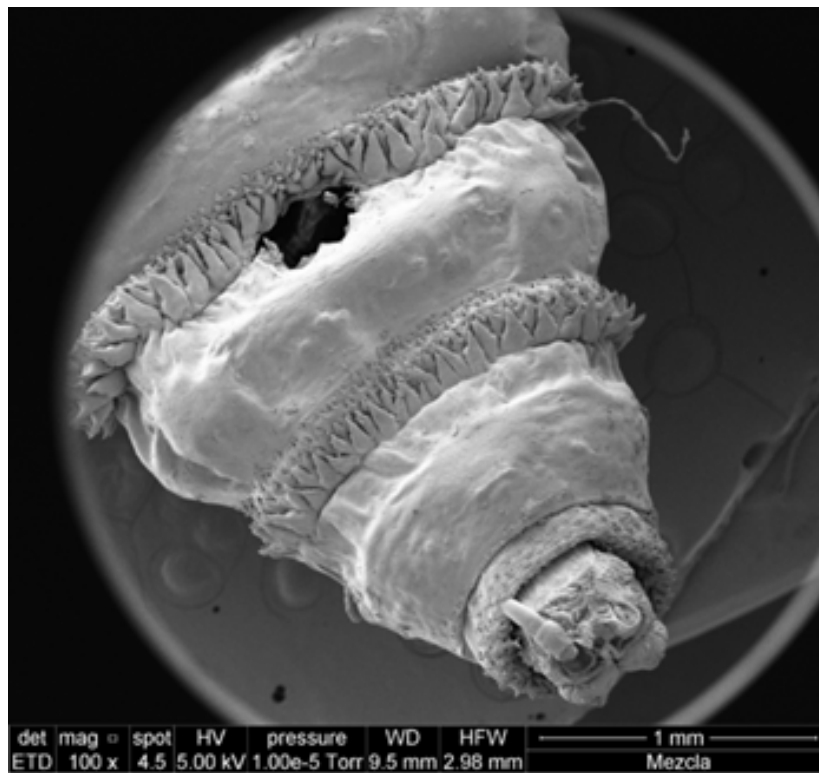

A. Optical microscopy

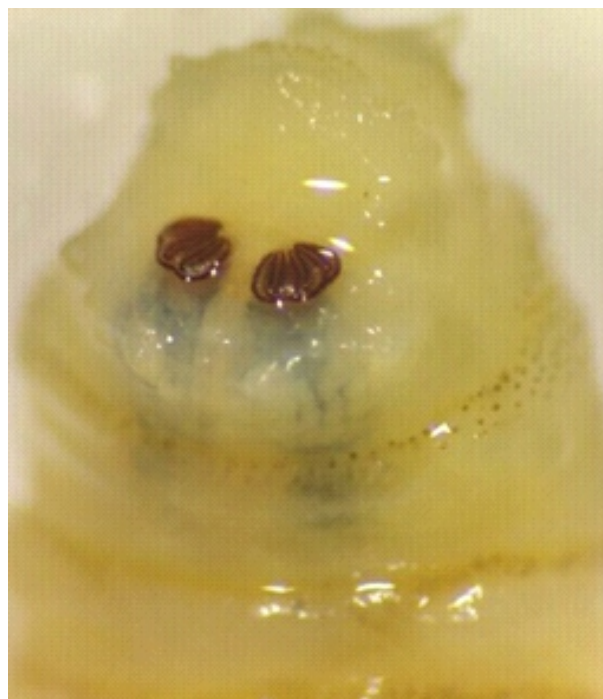

B. Electron microscopy

Figure 3. Anterior end of the L₃ of *Cochliomyia hominivorax* showing the detail of the hooks of the cephalopharyngeal skeleton.



A. Optical microscopy



B. Electron microscopy

Figure 4. Larva of third stage of *Cochliomyia hominivorax* showing the cuticular spines of one and two points.




Figure 5. Posterior spiracular plates of the third instar larva of *Cochliomyia hominivorax* showing characteristic respiratory stigmas and perithema.

ACKNOWLEDGMENT

Sources of financing: Control Laboratory of Arthropods and Vectors. National University of San Marcos. Faculty of Biological Sciences. Lima-Perú.

BIBLIOGRAPHIC REFERENCES

- Acha, P & Szyfres, B. 2003. *Zoonosis y enfermedades transmisibles comunes al hombre y a los animales*. 3ª ed. Washington DC: Organización Panamericana de la Salud. Vol III. Parasitosis. pp. 355-368. Publicación Científica y Técnica N° 580. Washington, DC 20037, EUA.
- Organización Panamericana de la Salud.
- Batista da Silva, J, Borja, G & Queiroz, M. 2011. Patient with tracheostomy parasitized in Hospital by larvae of the screwworm, *Cochliomyia hominivorax*. *Journal of Insect Science*, vol.11 pp.163.
- Botero, D & Restrepo, M. 2012. *Parasitosis Humanas*. 5ª ed. Ed. CIB Corporación para Investigaciones Biológicas. Medellín. 575-675 pp.
- Becerril, MA. 2014. *Parasitología Médica*. Capítulo 37: Artrópodos de importancia médica. 4ª edición Editorial McGraw-Hill. México. pp. 283-305.
- Calderón, O, Sánchez, C & Sandi, J. 1995. Miasis oral por *Cochliomyia hominivorax* (Diptera: Calliphoridae) en una paciente geriátrica. *Revista Costarricense de Ciencias Médicas*, vol. 16: 61-66.
- Carles-Tolrá, M. 2015. *Manual de la Clase Insecta: Orden Diptera*. Revista de la

- Sociedad Entomológica Aragonesa, vol. 63, pp. 1–22.
- Coronel, A, Sacta, B & Crespo, C. 2016. *Caso clínico: Miasis traumática*. Revista Médica del Hospital Jose Carrasco Arteaga (HJCA) Cuenca-Ecuador, vol. 8, pp. 82-85.
- Dale, W. 1985. *Identidad de las moscas Calliphoridae en la Costa Central de Perú*. Revista Peruana de Entomología, vol. 28, pp. 63-70.
- Domínguez, J, Cueva, J, Cusco, C, Rodríguez-Hidalgo, R & Calvopiña, M. 2016. *Miasis orbitaria severa causada por Cochliomyia hominivorax en la región andina de Ecuador*. Revista Mexicana de Oftalmología, vol. 90 pp. 43-47.
- Espinoza, A, Quiñones-Silva, J & Garay, O. 2009. *Miasis en cavidad oral por Cochliomyia hominivorax. Reporte de un caso*. Revista Peruana de Medicina Experimental y Salud Pública. vol. 26, pp.573-576.
- Failoc-Rojas, VE, Molina-Ayasta, Salazar-Zuloeta, J, Samamé, A & Silva-Díaz, H. 2018. *Case Report: Myiasis due to Cochliomyia hominivorax and Dermatobia hominis: clinical and pathological differences between two species in Northern Peru*. American Journal of Tropical Medicine and Hygiene, vol. 98 pp.150-153.
- Florez, E & Wolff, M. 2009. *Descripción y clave de los estadios inmaduros de las principales especies de Calliphoridae (Diptera) de importancia forense en Colombia*. Neotropical Entomology, vol. 38, pp. 418-429.
- Forero, E.; Cortés, J. & Villamil, L. 2007. *Ecología y Epidemiología del gusano barrenador del ganado, Cochliomyia hominivorax (Coquerel, 1858)*. Revista de Medicina Veterinaria, vol. 14, pp. 37-49.
- Francesconi, F & Lupi, O. 2012. *Myiasis*. Clinical Microbiology Reviews, vol. 25, pp.79-105.
- Graham, O.H. 1985. *Symposium eradication of the screwworm from the United States and Mexico. Miscellaneous*. Publications of the Entomological Society of Americana 62 pp.
- Gomez, M, Alvarez, A & Bonilla, J. 2008. *Manual de identificación de gusano barrenador del ganado Cochliomyia hominivorax (Coquerel) Diptera: Calliphoridae y su diferenciación de otras especies causantes de miasis*. Comisión México americana para la erradicación del gusano barrenador del ganado. pp. 1-71.
- Heizenreder, B, Fernández, R & Kulinka, L. 2009. *Un caso de miasis humana por Cochliomyia hominivorax (Diptera: Calliphoridae) asociado a varicela en Villa Angela, provincia del Chaco, Argentina*. Revista de Posgrado de la Cátedra de Medicina, vol. 192. pp.14- 16.
- Maguiña-Vargas, C, Osoreo, F, Farías, H, Torrejón, D & Alcorta, T. 2005. *Enfermedades por ectoparásitos: segunda parte*. Dermatología Peruana, vol.15, pp. 38-50.
- Mengarelli, R & Cevallos, M. 2012. *Manejo de las miasis en heridas agudas y crónicas. Presentación de casos y revisión de la bibliografía*. Revista Argentina de Dermatología, vol. 93, In: <http://www.scielo.org.ar/scielo.php>
- Miranda, H. 2007. *Miasis en Trujillo, Perú: observaciones clínicas y entomológicas*. Folia Dermatológica, vol.18 pp.13-17.
- Olea, M, Centeno, N, Veggiani, C, Ortega, E, Begoña, G, Olea, L & Dantur, J. 2014. *First report of myiasis caused by Cochliomyia hominivorax (Diptera: Calliphoridae) in a diabetic food ulcer patient in Argentina*. Korean Journal of Parasitology, vol.52 pp. 89-92.
- Páez, R & Villa, L. 2017. *Identificación de larvas productoras de miasis obtenidas del cepario de la Universidad Colegio Mayor de Cundinamarca con importancia en salud pública*. Revista NOVA Publicación Científica en Ciencias Biomédicas, vol.15, pp. 79-91.
- Pérez-Caballero, A, Garduño-Eseverri, E, Nicolás-Olivera, R & Pérez-Bote, L. 2012. *Lesión cutánea de etiología poco frecuente*. Enfermedades Infecciosas y Microbiología Clínica, vol.30, pp. 346–347.
- Pereira, J, Sant'Ana dos Santos, F, Farias, A, Salimon, F, Ferreira, F & Tadeu, A. 2015. *Oral myiasis caused by Cochliomyia hominivorax in a disabled person*. Case Reports in Pathology, vol. 2015, pp.1-3.
- Reinoso, Q.S. & Aleman, I.J. 2016. *Rara miasis maxilar por Cochliomyia hominivorax. Reporte de caso, actualidad y entomología*. Revista Española de Cirugía Oral y Maxilofacial, vol.38, pp.111-116.Seminario, M & Colán, E. 1990.

- Dermatobia hominis en carúncula ocular. Reporte de un caso en Iquitos Perú.* Diagnóstico, vol. 26 pp.95-96.
- Trombetta L, Oliva A, Galache V, Bava J & Troncoso A. 2009. *Cutaneous myiasis due to Cochliomyia hominivorax in a drug user.* Journal of Infection in Developing Countries, vol. 3, pp. 873-876.
- Villarreal, J, Agapito, J, Gutiérrez, J & Lavander, L. 1993. *Miasis genital: A propósito de un caso.* Revista de la Sanidad de la Policía Nacional del Peru, vol. 54. pp.72-75.
- Visciarelli, E, García, S, Salomón, C, Jofré, C & Costamagna, S. 2003. *Un caso de miasis humana por Cochlyomyia hominivorax (Diptera: Calliphoridae) asociado a pediculosis en Mendoza, Argentina.* Parasitologia Latinoamericana, vol. 58, pp.166-168.
- Zumpt, F. 1965. *Myiasis in man and animals in the old world.* Butterworths London. United Kingdom. pp.267.

Received September 21, 2018.
Accepted December 27, 2018.